



## Clinical, Radiographic and Microbiological Evaluation of Different Obturating Materials in Pulpectomy of Primary Molars

Selwan Elsherbeny<sup>1\*</sup>, Samy Y. Al- Bauomy<sup>2</sup>, Mohamed H. Mostafa<sup>3</sup>

Codex : 3-09/23.01

azhardentj@azhar.edu.eg

http://adjg.journals.ekb.eg

DOI: 10.21608/adjg.2022.94659.1406

Pediatric Dentistry & Orthodontics  
( Pediatric Dentistry, Orthodontics )

### ABSTRACT

**Purpose:** to assess the use of Zinc oxide and Eugenol, Endoflas and Plant flavonoid (hesperidin) as obturating materials in pulpectomy of primary molars by using clinical, radiographical and microbiological evaluation. **Material and Methods:** (In vivo study) a number of 90 primary teeth indicated for pulpectomy were divided equally into three groups according to the root canal obturating material. Group I (30 teeth) (control group) obturated with Zinc oxide and Eugenol material. Group II (30 teeth) obturated with Endoflas material. Group III (30 teeth) obturated with hesperidin extract and Zinc oxide material. A periapical radiograph was taken for each treated molar immediately postoperative, after 3 and after 6 months. Clinical and radiographic follow-up for success and failure was performed. The three obturating materials were evaluated against *Enterococcus faecalis* by using agar diffusion method. **Results:** after 6 months: Group II (Endoflas group) reported the highest success rate (100%), followed by Group I (ZnO/Eugenol group) (76.7%), with the least success value recorded in Group III (Hesperidin group) (60%). **Conclusions:** Endoflas material is a good alternative to ZnO/Eugenol in pulpectomy of primary molars.

### INTRODUCTION

When the primary tooth pulp become infected, pulp preservation of the primary tooth will be a major challenge for pediatric dentist. One of the treatment options in these cases is pulpectomy. The pulpectomy involves removal of necrotic or irreversibly infected pulp of the infected

### KEYWORDS

*Pulpectomy, Endoflass,  
Hesperidin, ZnO/Eugenol.*

- Paper extracted from Doctor thesis titled “Clinical, Radiographic and Microbiological Evaluation of Different Obturating Materials in Pulpectomy of Primary Molars”
- 1. Assistant Lecturer of Pedodontics and Oral Health, Faculty of Dental Medicine for Girls, Al-Azhar University, Cairo, Egypt.
- 2. Professor of Pedodontics and Oral Health, Faculty of Dental Medicine for Boys, Al-Azhar University, Cairo, Egypt.
- 3. Assistant Professor of Pedodontics and Oral Health, Head of Pedodontics and Oral Health Department, Faculty of Dental Medicine for Girls, Al-Azhar University, Cairo, Egypt.

\* Corresponding author email: selwanalsherbeny.26@azhar.edu.eg

tooth<sup>(1)</sup>. The success of endodontic treatment is highly dependent on the obturating material, therefore, obturating material with antimicrobial properties is required in deciduous teeth<sup>(2)</sup>.

Zinc oxide and Eugenol paste is one of the most widely used materials for primary tooth pulpectomies. The advantages of ZOE are anti-inflammatory and analgesic properties, greater zone of bacterial inhibition, availability, radiopacity of material, cheaper, insolubility in tissue fluids, easy to mix, and good working time<sup>(3)</sup>.

Another synthetic material is Endoflas paste. The advantage of Endoflas is that its resorption is limited to the excess material. This means that the material is neither resistant to resorption nor does it result in the hollow tube effect<sup>(4)</sup>. The ideal biomechanical endodontic treatment for the root canals of primary teeth is hard to achieve due to their fenestrated and tortuous nature<sup>(5)</sup>.

Hesperidin (herbal extract) is natural plant flavonoids from the Citrus species that exhibit various biological properties. Herbal extracts are known for their including antioxidant, anti-inflammatory, anticancer and antimicrobial effects<sup>(6)</sup>. This present study was planned to evaluate and compare by clinical, radiographical, and microbiological methods the effect of three materials, Zinc oxide +Eugenol, Endoflas and Plant flavonoid (Hesperidin extract) as obturating materials in pulpectomy of primary molars.

## MATERIAL AND METHODS

### Study design and ethical approval

This study included (90) badly decayed primary molar teeth that were indicated for pulpectomy. These teeth were selected from age range from (4-8) years child patients of Pediatric Dentistry Outpatients Clinic, Faculty of Dental Medicine, Al-Azhar University. Research Ethics Committee approval with code (REC18-077) was obtained from Faculty of Dental Medicine for Girls, Al-Azhar University.

### Informed Consent

All details of procedures, possible discomfort and benefits of this study were explained to the guardians and informed written consents were signed before children enrollment in the study.

### Sample calculation

Assuming an alpha ( $\alpha$ ) level of 0.05 (5%) and a Beta ( $\beta$ ) level of 0.20 (20%) i.e., power=80% and an effect size ( $w$ ) of (0.37); the predicted sample size ( $n$ ) was a total of (90) samples i.e. (30) for each group. Sample size calculation was performed using G\*Power version 3.1.9.2<sup>(5)</sup>.

### Clinical and radiographic examination

Before treatment, detailed medical and dental histories were obtained then clinical and radiographic examinations were done. Patient information was collected and recorded in the patient examination chart. Preoperative radiographic assessment was done by periapical radiographs.

### Randomization and Blinding Procedures

Following consent, participants were sequentially randomized, using a computer-generated random number list. The randomly generated sequence was enclosed in sealed envelopes to ensure the allocation concealment. The envelopes were randomly picked up by the children for group allocation. Follow up evaluations were carried out by a calibrated examiner who was not participant in the treatment procedures. There was no blinding.

### Inclusion criteria<sup>(6)</sup>

This study included (90) badly decayed primary molar teeth that were indicated for pulpectomy in healthy children ranging from 4 -8 years old of both sexes who met the inclusion criteria. Inclusion criteria were absence of any systemic disease which would contraindicate pulp therapy, cooperative patients, and restorable primary molars with inflamed or necrotic pulp that were indicated for pulpectomy.

Teeth with mobility, physiologic root resorption and the unrestorable teeth that are not indicated for pulpectomy were excluded from the study.

### Subject Selection

The selected primary molars were classified into three equal groups (I, II and III) based on the obturating material used for pulpectomy. In each group (n=30) molars.

#### Group I

In this group (n=30) molars received pulpectomy and obturated with Zinc oxide and eugenol.

#### Group II

In this group (n=30) molars received pulpectomy and obturated with Endoflas.

#### Group III

In this group (n=30) molars received pulpectomy and obturated with Hesperidin and Zinc oxide.

### Protocol for intervention

#### The Pulpectomy Technique;<sup>(7,8)</sup>

Local anesthesia was injected, and patients waited for 10 to 15 minutes before pulpectomy procedure was undertaken. The teeth were isolated with rubber dam then a sterile high-speed round steel bur was used for caries removal. A sharp spoon excavator was used for necrotic coronal pulp removal then the coronal pulp chamber was irrigated with 2.5% NaOCl and saline.

The pulp tissue was extirpated from the canals with barbed broach and to confirm the working length, an intraoral periapical radiograph was taken. Canals were mechanically instrumented with manual files up to size 20/02 K files. The preparation of root canals was done with rotary endo motor using FANTABAF baby files (rotational speed was 300 rpm, at the lowest torque setting). The file was coated with 18% EDETA gel for each canal, then

after each file, irrigation with 2.5% NaOCl then saline alternatively and a sterile paper point were used for drying the canals.

After that the root canals were obturated 1 mm short from the apex with one of the three tested obturating materials using incremental technique and condensation with hand plugger. The present study was a double-blinded, prospective randomized clinical trial where the patient and the outcome assessors were not aware about the material used for obturation. The proportions used in this study to achieve the ideal consistency of the material are detailed in the following: (Table 1).

**Table (1)** Powder and liquid ratios of the tested filling materials.

Material	Powder	Liquid
<b>Zinc oxide and Eugenol</b>	4 powder 0.28: mg by weight proportion Powder (zinc oxide).	1 liquid 0.07 mg by weight (Eugenol)
<b>Endoflas</b>	4 powder 0.28: mg by weight proportion powder (zinc oxide, barium sulfate, triiodomethane and calcium hydroxide).	1 liquid 0.07 mg by weight liquid (eugenol, paramonochlorophenol).
<b>Hesperidin and zinc oxide</b>	3 powder powder was mixed in increments with liquid using the folding technique. Then greenish clay was resulted. The mix was freshly prepared just prior to its use.	1 liquid Sterile distilled water

### Follow up

Criteria for Clinical Evaluation after 3 and 6 Months were Presence or absence of; pain, swelling, abscess, draining fistula and mobility. On each visit, the pulpectomy procedure considered to be clinically successful when tooth was asymptomatic (i.e., without pain, tenderness, abscess, and mobility). Radiographic evaluation was done immediately postoperative and at 3- and 6-months follow-up the molar was radiographically considered as successful in case of reduction in the size of interradicular radiolucency or the size remaining same and also when no signs of internal or external pathological root resorption were noticed. (Fig. 1,2,3)

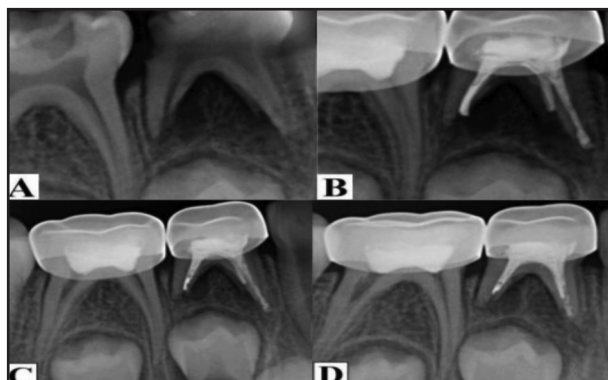


Figure (1): (A) Preoperative, (B) Postoperative, (C) After three months follow up and (D) After six months follow up radiographs for Zinc oxide and eugenol pulpectomy in mandibular first primary molar.

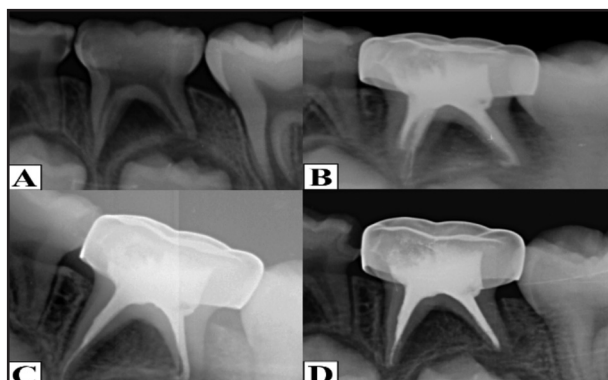


Figure (2): (A) Preoperative, (B) Postoperative, (C) After three months follow up and (D) After six months follow up radiographs for Endoflas pulpectomy in mandibular second primary molar.

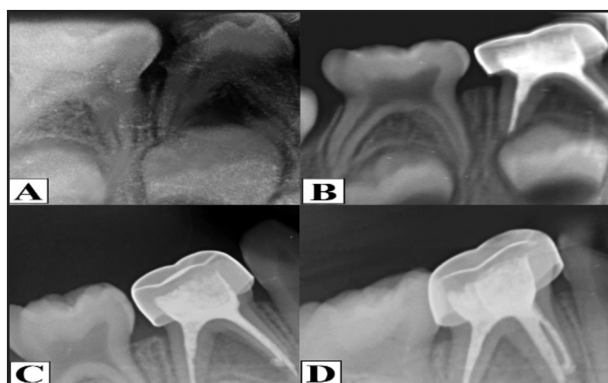

Figure (3): (A) Preoperative, (B) Postoperative, (C) After three months follow up and (D) After six months follow up radiographs for Hesperidin and Zinc oxide pulpectomy in mandibular first primary molar.

## RESULTS

### Statistical analysis:

Statistical analysis was performed using a commercially available software program (SPSS 19; SPSS, Chicago, IL, USA). Qualitative values were presented as number and percentages. Chi square test was used to compare categorical data. Quantitative values (age) were expressed as mean and standard deviation and were compared between groups using ANOVA. Microsoft excel was used for generation of representative figures. The level of significance was set at  $P \leq 0.05$ .

### Clinical success

#### Comparison between groups

At 3 months, Group II (Endoflass group) reported the highest success rate (100%), followed by Group I (ZnO/Eugenol group) (86.7%), with the least value recorded in Group III (Hesperidin group) (66.7%). Chi square test revealed a statistically significant difference between groups ( $p=0.0016$ ), (Table 2).

At 6 months, Group II (Endoflass group) reported the highest success rate (100%), followed by Group I (ZnO/Eugenol group) (76.7%), with the least value recorded in Group III (Hesperidin group) (60%). Chi square test revealed a statistically significant difference between groups ( $p=0.0007$ ), (Table 2).

### Radiographic success

#### Comparison between groups

At 3 months, Group I (ZnO/Eugenol group) and Group II (Endoflass group) reported the highest success rate (100%), while the least value recorded in Group III (Hesperidin group) (76.7%). Chi square test revealed a statistically significant difference between groups ( $p=0.0005$ ), (Table3).

At 6 months, Group II (Endoflass group) reported the highest success rate (90%), followed by Group I (ZnO/Eugenol group) (80%), with the least value recorded in Group III (Hesperidin group) (60%). Chi square test revealed a statistically significant difference between groups ( $p=0.019$ ), (Table3).

**Table (2):** Clinical success in different groups at 3 and 6 months.

Time	Group I (ZnO/Eugenol group)		Group II (Endoflass group)		Group III (Hesperidin group)		X <sup>2</sup>	P
	Success	Failure	Success	Failure	Success	Failure		
3 months	26 (86.7%)	4 (13.3%)	30 (100%)	0	20 (66.7%)	10 (33.3%)	12.86	0.0016*
6 months	23 (76.7%)	7 (23.3%)	30 (100%)	0	18 (60%)	12 (40%)	14.54	0.0007*
X <sup>2</sup>	1.002		0		0.287			---
P	0.317ns		1ns		0.592ns			

Significance level  $p < 0.05$ , \* significant, ns= non-significant.

**Table (3):** Radiographic results in different groups at 3 and 6 months.

Time	Group I (ZnO/Eugenol group)		Group II (Endoflass group)		Group III (Hesperidin group)		X <sup>2</sup>	P
	Success	Failure	Success	Failure	Success	Failure		
3 months	30 (100%)	0	30 (100%)	0	23 (76.7%)	7 (23.3%)	15.18	0.0005*
6 months	24 (80%)	6 (20%)	27 (90%)	3 (10%)	18 (60%)	12 (40%)	7.826	0.019*
X <sup>2</sup>	6.66		3.16		1.926			-----
P	0.009*		0.076ns		0.165ns			

Significance level  $p < 0.05$ , \* significant, ns= non-significant.

## Microbiology results

The three materials were tested in agar diffusion media plates and inhibition zone against *E. Faecalis* was measured in every group for five times with total 15 samples for all groups and then the results were statistically analyzed. The greatest inhibition zone was recorded in Group II (Endoflass group) then by Group I (ZnO/Eugenol group), while Group III (Hesperidin group) showed least inhibition zone. ANOVA test and Tukey's post hoc test revealed a significant difference between groups ( $p=0.00$ ).

## DISCUSSION

The basic target of pulpectomy is to eliminate infection and maintain the tooth in a functional state until it is normally exfoliated. Debridement of the root canal system is not the only management of the infected primary teeth, but it involves also obturation by using a material which is biocompatible and could resorb at the same rate as the roots of the involved tooth, without endangering the underling permanent tooth successor and not affecting its path of eruption<sup>(3,7)</sup>.

The present study was divided into two parts. The first part (in vivo study) was concerned by evaluation of the effect of Zinc Oxide and eugenol, Endoflas and Hesperidin in pulpectomy procedures for primary teeth clinically and radiographically. The second part was a microbiological study to evaluate the effects of these materials on *Enterococcus faecalis* bacteria. For the clinical and radiographic part of the study, patients were selected with an age range of 4 to 8 years old irrespective of their sex to obtain good patient cooperation which may be absent because of lack of cooperation in younger age group.

This age range also give more accurate results as the starting of physiologic root resorption would not exert a confounding effect<sup>(8)</sup>. The present study revealed no significant difference between groups regarding to the age and gender of patients. Single-visit endodontic treatment was the choice in our study because it is less painful than multi-visit treatment. A second visit means added discomfort due to local anesthetic or trauma from a rubber dam application.

The present study revealed high success rate after six months follow up in Endoflas group. The clinical success was (100%) and (90%) radiographic success compared to Zinc oxide and Eugenol group where the clinical success was (76.7%) and (80%) for radiographic success. These observations are in accordance with the investigations of the past decade<sup>(9,10)</sup>. Endoflas has been clinically and radiographically evaluated for 9 months in a previous study and reported an overall success rate of 95.1% compared to metapex<sup>(11)</sup>.

In another study Endoflass was observed with 100% success over ZOE (84%) at 9-month follow-up<sup>(12)</sup>. The difference in success rate could be due to the influence of various factors. Variation in the failures may be due to the individual body resistance or related to the pathologic condition of the tooth preoperative<sup>(13)</sup>. Another important factor is the age

of the patients and their behavior, which together make such research more difficult rather than to the filling technique<sup>(14)</sup>.

The prognosis was better in this study if the tooth was devoid of periapical pathology and root resorption before pulpectomy. It was demonstrated that severe preexisting infection has less chance to be resolved by the pulpectomy procedure similarly, teeth with preexisting pathology resulted in low success rate<sup>(14,15)</sup>.

In the third group, hesperidin, the herbal product was used as pulpectomy material. The use of plants and plant extracts for medicinal purposes has experienced remarkable advancement in recent years, similarly, the use of biocompatible substances has become a major area of interest in modern dentistry<sup>(16)</sup>. Herbs have high antimicrobial, anti-inflammatory, antioxidant (due to the presence of wide variety of active phytochemicals, including flavonoids, terpenoids, lignans, sulfides, polyphenolics, carotenoids, coumarins, saponins, plant sterols, curcumin) and biocompatible properties making their use in dentistry more extensive<sup>(17,18)</sup>.

Presently no data are available in the literature on Hesperidin usage as a constituent of root canal obturation in primary teeth. The herbal extracts were mixed in many articles with the existing filling materials. The Endoflas powder was mixed with Curcumin gel and Aloe vera gel then used as obturating material and exhibited faster resorption of the over pushed material within 1 week follow up with decrease in inter-radicular radiolucency after 1 month and maintained until the 3rd month follow-up<sup>(19)</sup>.

In our study Hesperidin showed the lowest antimicrobial effect against *E. faecalis* and the lowest clinical and radiographical success. Further studies are needed for assessment of the antimicrobial effect of Hesperidin alone and in combination with other materials with different concentrations.

## CONCLUSION

Regarding the results obtained from this study, we could conclude that Endoflas is the material that has more antimicrobial effect against *E. faecalis* and showed the highest success rate clinically and radiographically, so it is considered as good alternative to ZOE. Another conclusion is that Hesperidin has low antimicrobial effect against *E. faecalis* and low clinical and radiographic success results.

## ACKNOWLEDGMENTS

To all the children and their guardians who contributed to the study without whom the study could not have been feasible.

## RECOMMENDATIONS

Further clinical, radiographical and histological studies with larger sample size and longer follow up periods are required. Additional studies against other bacterial strains with different material concentrations are needed to evaluate the effect of hesperidin in pulpotomy and pulpectomy of primary teeth.

## Conflict Of Interest

No conflict of interest.

## Funding

No funding was received for this study.

## REFERENCES

- Xiaoxian Chen, Jie Zhong. Clinical and radiographic evaluation of pulpectomy in primary teeth: an 18-months clinical randomized controlled trial. *Head & Face Med.* 2017;13:12017-45.
- Moranker R, Goya A, Gauba K. Manual versus rotary instrumentation for primary molar pulpectomies: A 24-months randomized clinical trial. *Ped Dent J.* 2018;28:96-102.
- Rawson TH, Rayes S, Strizich G, Salazar CH. Longitudinal study comparing pulpectomy and pulpotomy treatments for primary molars of Alaska Native children. *Ped Dent.* 2019;41:214-20.
- Rafatjou R, Yousefimashouf R, Farhadian M, Afzalsoltani S. Evaluation of the antimicrobial efficacy of two combinations of drugs on bacteria taken from infected primary teeth (in vitro). *Eur Arch Ped Dent.* 2019;20:609-15.
- Delfabbro M, Afrashtehfar K, Corbella S, ElKabbaney A, Perondi I. In vivo and in vitro effectiveness of rotary nickel-titanium vs manual stainless-steel instruments for root canal therapy a systematic review and meta-analysis. *J Ev Dent* 2017;22:102-10.
- Tinoco J, Less N, Zhang H, Nissan R, Gordon W, Tinoco E, et al. Antibacterial effect of genetically engineered bacteriophage on dentin infected with antibiotic-resistant *Enterococcus faecalis*. *Arch Oral Biol.* 2017;82:166-70.
- Pandranki J, V Vanga NR, Chandrabhatla SK. Zinc oxide eugenol and Endoflas pulpectomy in primary molars a 24-month clinical and radiographic evaluation. *J Indian Soc Pedod Prev Dent.* 2018;36:173-99.
- Aminabadi NA, Asl Aminabadi N, Jamali Z, Shirazi S. Primary tooth pulpectomy overfilling by different placement techniques A systematic review and meta-analysis. *J Dent Res Dent Clin Dent Pros.* 2020;14:250-61.
- Duarte M.L, Pires P.M, Ferreira D.M. Is there evidence for the use of lesion sterilization and tissue repair therapy in the endodontic treatment of primary teeth. A systematic review and meta-analyses. *Clin Oral Invest.* 2020;24:2959-72.
- Patel BS, Choudhari SR, Goyal S, Patel CB, Waghela SA. Clinical and radiographical evaluation of single- versus multiple-visit pulpectomy treatment in primary teeth with apical periodontitis. *Indian J Dent Sci.* 2020;12:225-31.
- Tedesco, Tamara Kerber . Management of deep caries lesions with or without pulp involvement in primary teeth: a systematic review and network meta-analysis. *Braz oral res.* 2021;35:1-4.
- Gomes LAS, Oliveira AA, De Campos, Neves ATS. Technology Incorporation in Primary Teeth Endodontics: Case Reports. *Int J Clin Ped Dent.* 2020; 13:180-85.
- Vinay K. Chugh, Arun K. Patnana, Ankita Chugh, Pravin Kumar, Puneet Wadhwa, Surjit Singh. Clinical differences of hand and rotary instrumentations during biomechanical preparation in primary teeth a systematic review and meta-analysis. *Inter J Ped Dent.* 2020;31:131-42.
- Miguez P.A, Tuin S.A, Robinson A.G. Hesperidin Promotes Osteogenesis and Modulates Collagen Matrix

- Organization and Mineralization In Vitro and In Vivo. *Int J Mol. Sci.* 2021;22:3222-32.
15. Coll, James A, Kaaren, Marghalani, Abdullah A ,Chia-Yu, et al. Systematic Review and Meta-Analysis of Nonvital Pulp Therapy for Primary Teeth. *Ped Dent.* 2020; 42: 256-461.
  16. Viviane Cancio, Dennis de Carvalho Ferreira, Fernanda Sampaio Cavalcante. Can the *Enterococcus faecalis* identified in the root canals of primary teeth be a cause of failure of endodontic treatment. *Acta Odon Scand.* 2017;75: 6423-428.
  17. Coll JA, Vargas K, Marghalani A. A systematic review and meta-analysis of nonvital pulp therapy for primary teeth. *Ped Dent.* 2020; 42:256-72.
  18. Abo El-Mal EO, Abu-Seida AM, El Ashry SH. Biological evaluation of hesperidin for direct pulp capping in dogs' teeth. *Int J Exp Path.* 2021; 102:32–44.
  19. Divya DV, Prasad MG, Radhakrishna AN, Sandeep RV, Reddy SP, Santosh Kumar KV. Triple antibiotics paste versus propolis: A clinical quest for the reliable treatment of periapical lesions in primary molars. *Saudi Endo J.* 2019; 9:34-9.