



Effect of XP-endo Finisher on Post-Instrumentation Pain after Using Different NiTi Rotary Systems

Mai S. Hanafy^{1*}, Wael H. Kamel², Mohsen M. Nour El Din³

Codex : 21/2004

azhardentj@azhar.edu.eg

http://adjg.journals.ekb.eg

DOI: 10.21608/adjg.2020.7531.1078

Restorative Dentistry
(Removable Prosthodontics, Fixed
Prosthodontics, Endodontics, Dental
Biomaterials, Operative Dentistry)

ABSTRACT

Purpose: This study was conducted to assess and compare the effect of XP-endo Finisher on post-instrumentation pain after using either One Shape single-file rotary system or ProTaper Universal multi-file rotary system in root canal preparation. **Materials and Methods:** Forty-eight consented patients, with 52 single-rooted teeth requiring endodontic treatment were selected for this study based on inclusion/exclusion criteria. Teeth were randomly assigned into two equal groups according to the NiTi rotary system used for root canal preparation, Group (I), One Shape rotary system was used and Group (II), ProTaper Universal rotary system was used. Each group was further subdivided into two equal subgroups (A and B) according to whether XP-endo Finisher was used in finishing the root canal preparation or not. Pain Intensity was measured using modified visual analogue scale at 6, 12, 24 and 72 hours after root canal instrumentation. **Results:** The patients' highest mean pain scores occurred in the first 24 hours and significantly declined at the subsequent observation time of 72 hours. ProTaper Universal groups showed the highest mean pain scores, while the lowest mean pain scores were found in One Shape groups with no significant difference. The highest mean pain scores were found in XP-endo Finisher subgroups, while the lowest were found in No XP-endo Finisher subgroups with no significant difference. **Conclusion:** One Shape system produced less postoperative pain when used in conjunction with XP-endo Finisher.

KEYWORDS

Post-instrumentation pain,
One Shape,
ProTaper Universal,
XP-endo Finisher

INTRODUCTION

Root canal chemomechanical debridement and hermetic seal with no discomfort to the patient are the main objectives of endodontic therapy. Unfortunately, postoperative pain is still an unwanted sensation that

- Paper extracted from Doctor Thesis titled "Effect of XP-endo Finisher on Post-Instrumentation Pain and Periapical Healing after Using Different NiTi Rotary Systems"

1. Assistant Lecturer of Endodontics, Faculty of Oral and Dental Medicine, Badr University, Cairo, Egypt
2. Professor and Head of Endodontic Department, Faculty of Dental Medicine for Girls, Al-Azhar University, Cairo, Egypt
3. Professor of Endodontics, Endodontic Department, Faculty of Dental Medicine for Girls, Al-Azhar University, Cairo, Egypt

* Corresponding author email: maiesayed@gmail.com

frequently occur after root canal treatment. Multiple factors may predispose for such pain where periapical tissues' injury takes place either chemically, mechanically and/or microbial, resulting consequently in acute inflammation (1-3).

The risk of flare-ups can be effectively minimized by diligent root canal cleaning and shaping(4). Several rotary systems, consist of 2 or more files, were launched to the market over the past few years for proper shaping of the root canals. Single-file technique was recently introduced as well to decrease time consumption during preparation(5). However, debridement of the entire root canal system is reported to be very difficult even with the introduction of these different instrumentation techniques (6,7). So, finding other means to properly clean and shape all aspects of the root canals became mandatory.

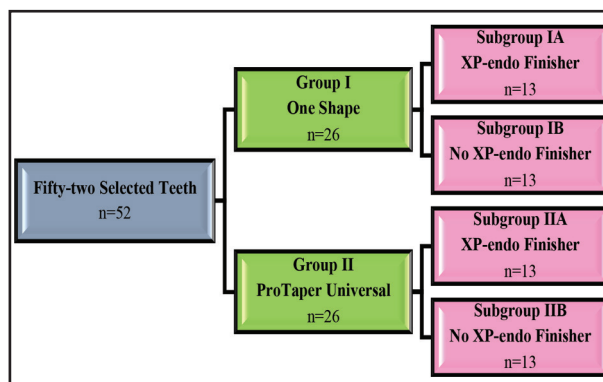
The new rotary nickel titanium (NiTi) file, XP-endo Finisher, was introduced to treat root canals with highly complex morphologies and getting optimal cleaning of the root canal especially in hard-to-reach areas while preserving dentin (8,9). However, there is limited information available regarding endodontic treatment outcome after using this new file in conjunction with different rotary systems.

Therefore, this study was conducted to assess and compare the effect of XP-endo Finisher on post-instrumentation level of pain after using either single-file rotary system or multiple-file rotary system.

MATERIALS AND METHODS

A total of forty-eight consented patients, with 52 anterior/premolar teeth requiring endodontic treatment, were enrolled from the pool of patients in the Dental Hospital at Faculty of Oral and Dental Medicine, Nahda University in Beni Suef, Egypt. Medically free, 20 to 40 years old patients with asymptomatic, necrotic, single-rooted, single-canal teeth showing radiographically visible periapical radiolucency ≤ 5 mm in diameter were participated in the study.

The fifty-two selected teeth were randomly assigned into two equal groups (I and II), (26 teeth each), according to the NiTi rotary system used in root canal instrumentation, Group I: One Shape (Micro-Mega, Besancon, France) rotary system was used, and Group II: ProTaper Universal (Dentsply, Maillefer, Tulsa Dental, USA) rotary system was used. Each group was further subdivided into two equal subgroups (A and B), (13 teeth each), according to whether XP-endo Finisher (FKG Dentaire SA, La Chaux-de-Fonds, Switzerland) was used in finishing the root canal preparation or not (Fig. 1).



Figure(1) Grouping of Samples.

In the first visit, a preoperative baseline pain level reading was taken using modified visual analogue scale (modified VAS). Then, each tooth was anesthetized by one carpule of 1.8 ml mepivacaine with vasoconstrictor for the purpose of rubber dam placement as well as to ensure the absence of discomfort during the treatment.

After anesthesia, rubber dam was applied on the assigned tooth to obtain proper field isolation. Access cavity preparation was done using sterile round bur # 3 (Komet, GmbH &Co, Germany) and Endo-Z bur (Dentsply Maillefer, Tulsa Dental products, USA) then glide path was established. Working length was determined to be 0.5-1 mm shorter than radiographic apex using an electronic apex locator and confirmed with intraoral periapical radiograph. Root canals with initial files equivalent to K-file #25 were the only included in the study.

Root canals were mechanically prepared in a crown-down approach using either the One Shape rotary system or ProTaper Universal rotary system mounted in 16:1 reduction handpiece powered by endodontic motor (SybronEndo motor, Sybron Dental Specialties, Glendora, CA, USA). In both techniques, the manufacturer's instructions were strictly followed.

In Group I, coronal flaring was done using Endoflare file (Micro-Mega, Besancon, France) - in an endodontic motor at a rotational speed of 400 rpm and torque 3 Ncm - to remove coronal restrictions and dentinal overhangs. Root canal preparation was done with the One Shape Apical 2 file (#37, 0.06 taper) in an endodontic motor at a rotational speed of 400 rpm and torque 2.5 Ncm. In Group II, root canal preparation was carried out using ProTaper Universal rotary system's files in an endodontic motor at a rotational speed of 300 rpm and torque adjusted for SX at 3-4 Ncm, S1 at 2-3 Ncm, S2 at 1-1.5 Ncm, and F1 till F4 at 2-3 Ncm. The SX was used first for coronal flaring followed by S1 to the full working length. Then S2, F1 till F4 were used to the full working length. Each file was lubricated using EDTA gel (MD-ChelCream, Meta Biomed Inc., USA).

All the canals were thoroughly irrigated during the whole preparation procedure with 2ml of 2.6%

NaOCl (Clorox, Household Cleaning Products, Company of Egypt Ltd, Egypt) between every two successive instruments with the aid of a side-vented irrigation needle (Endo-Eze Irrigator Tip, Ultradent, South Jordan, UT, USA) placed passively into the canal without binding. After complete instrumentation, each canal was irrigated with 1 ml of 17% EDTA solution (ENDO-Solution, CERKAMED, Medical Company, Poland) for 1 min to remove smear layer then canal was flushed again with 5 ml of 2.6% NaOCl for 1 min followed by 10 ml of distilled water (Egypt Otsuka Pharmaceutical company, S.A.E., Egypt) which were used as a final flush for the root canals.

In subgroups A, XP-endo Finisher (#25/0 taper) was used before the final flush irrigation protocol. The XP-endo Finisher file was used according to the manufacturer's instructions in an endodontic motor operated at 800 rpm speed and 1 Ncm torque. After filling the root canal with 2.6% NaOCl, the finisher was operated for 60 seconds using slow and gentle, 7-8 mm, in-and-out movements (**Fig. 2**). Then, the canal was soaked with 1 ml of 17% EDTA solution for 1 min and flushed again with 5 ml of 2.6% NaOCl for 1 min followed by 10 ml of distilled water which were used as a final flush for the root canals.

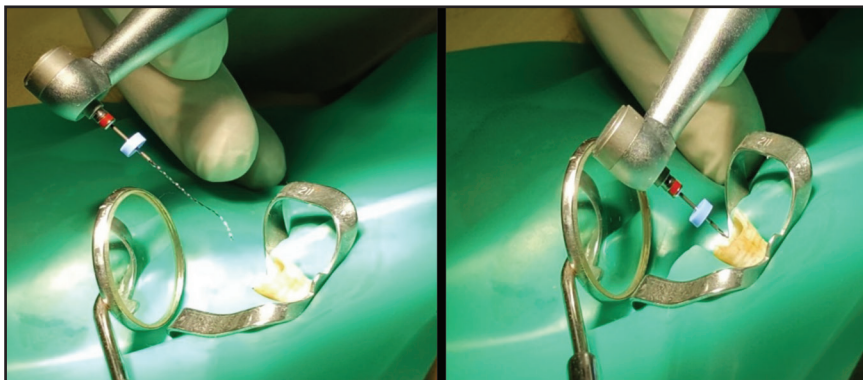


Figure (2) XP-endo Finisher operated using slow in-and-out movements in lower central incisor.

After the final irrigation protocol, root canals were dried with sterile paper points and access cavity was temporarily sealed.

Modified VAS pain diary was given to each patient and post-instrumentation pain level was recorded at 6, 12, 24 and 72 hours after the first visit. Patients were advised to call the investigator if they felt any unpleasant sensation during the follow-up period and were instructed strictly not to take medications without telling the investigator. If the patients complained of moderate to severe pain, they were allowed to take Ibuprofen (400 mg). If there was still pain indicating a flare-up (emergency), the patients were informed to contact the dentist and came to the clinic for an emergency intervention.

After 3 days, the patient was given an appointment for obturation. In the second visit, the pain diary of the patient was checked for the marks to evaluate the intensity and frequency of pain. Then, each tooth was anesthetized by one carpule of local anesthetic solution for the purpose of rubber dam placement as well as to ensure the absence of discomfort during the dental procedure. Rubber dam was placed followed by temporary restoration removal and irrigation with 5 ml of 2.6% NaOCl for 1 min and 10 ml of distilled water was done. The root canal was then dried using paper points and obturated by modified single cone technique.

The data were analyzed statistically using IBM® SPSS® Statistics Version 20 for Windows and the significance level was set at $P \leq 0.05$.

RESULTS

In group (I) (One Shape), there were significantly high mean pain scores at 6 hrs, that increased and peaked at 12 hrs, then decreased at 24 hrs, and significantly declined at 72 hrs. Also, in group (II) (ProTaper Universal), there were significantly high mean pain scores at 6 hrs, that increased and peaked at 12 hrs, then decreased at 24 hrs, and significantly declined at 72 hrs as shown in (Fig. 3).

In group (I) (One Shape), the XP-endo Finisher subgroup showed higher modified VAS mean pain scores than the no XP-endo Finisher subgroup with no statistically significant difference between both subgroups ($p=0.486$). Also, in group (II) (ProTaper Universal), the XP-endo Finisher subgroup showed higher modified VAS mean pain scores than the no XP-endo Finisher subgroup with no statistically significant difference between them ($p=0.366$) (Fig. 4).

In subgroup (A) (XP-endo Finisher), the highest modified VAS mean pain scores were found in ProTaper Universal group, while the lowest mean scores were found in One Shape group but still with no statistically significant difference where

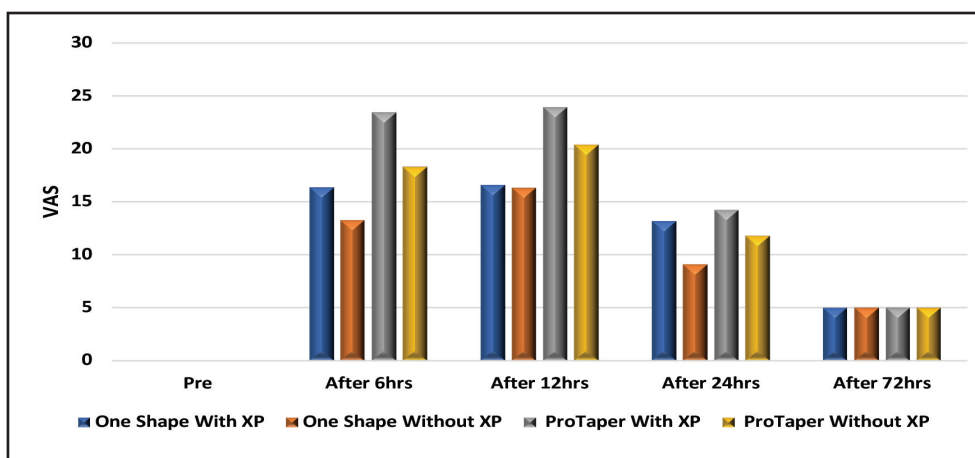


Figure (3) Bar chart representing modified VAS scores at different follow-up periods between the tested groups.

$p=0.382$. Also, in subgroup (B) (No XP-endo Finisher), ProTaper Universal group showed higher modified VAS mean pain scores than the One Shape group but with no statistically significant difference where $p=0.429$ (Fig. 4).

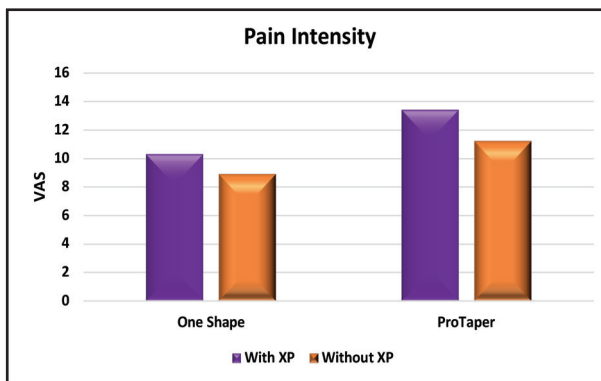


Figure (4) Bar chart representing pain intensity in One Shape and ProTaper Universal groups.

DISCUSSION

Root canal system chemomechanical preparation and three-dimensional sealing with no discomfort to the patient is the primary aim of performing endodontic treatment. However, untouched root canal surfaces reached a percentage of 35% or more regardless of the shaping technique used⁽¹⁰⁾. So, instrumentation alone does not completely prepare root canals for obturation, and disinfection is a crucial step to augment the instrumentation process and optimize root canal obturation⁽¹¹⁾.

XP-endo Finisher is an exceptional file that was designed to complete the preparation that has been attained with either rotary or reciprocating files, reaching spaces and canal wall aspects that were not shaped with the standard instrumentation techniques. Being compatible with all root canal preparation systems, the finisher rotary instrument promises to complete the incomplete job of physically reaching all surfaces of the root canal system⁽¹²⁾.

In the present study, post-instrumentation pain intensity was measured preoperatively as a baseline record and postoperatively at 6-, 12-, 24- and

72-hr intervals after the first visit. These follow-up periods were selected in conformance with studies which showed that postoperative pain is more likely to happen in the first 24 hours, then decreases afterwards as time passes and reduces considerably to minimal levels⁽¹³⁻¹⁵⁾.

Pain experience, being an intricate phenomenon, is influenced by different factors either physically, psychologically and/or environmentally. Accordingly, a fully comprehended and easily interpreted pain evaluation method must be used to ensure proper pain assessment⁽¹⁶⁾. Being considered as a valid, easy and reliable way of pain measurement^(17,18), the visual analogue scale (VAS) was used in this study. This method, being applied in a variety of practice settings, is reported to be more sensitive to small changes in pain, reproducible, independent of language, and easily understood⁽¹⁹⁻²³⁾.

The results of the present study revealed that the patients' highest post-instrumentation pain scores were recorded during the first 24 hours. At the 6th hour interval and after the anesthesia effect subsided, there were significantly high post-instrumentation pain levels that increased and peaked at the 12th hour and declined gradually thereafter. This is in accordance with several studies^(14,24-27) where high pain scores were recorded by the patients at the first 24 hours and then decreased considerably in the subsequent follow-up time points. This recorded pain might be attributed to the expression of pro-inflammatory mediators such as prostaglandins, leukotrienes, serotonin, histamine and bradykinin (pain mediators) and neuropeptides such as substance P and calcitonin gene-related peptide from C-type nerve fibers present in the periodontal ligament following instrumentation of the root canal which initiate inflammatory responses during the first 24 hours and recedes thereafter⁽²⁸⁻³¹⁾.

In this study, the ProTaper Universal multi-file system showed slightly higher mean pain scores than the One Shape single-file system with no statistically significant difference. There is lack of

studies that compare the intensity of postoperative pain when shaping the root canals with One Shape and ProTaper Universal. However, a significantly higher postoperative pain was stated to happen for patients undergoing root canal preparation with ProTaper Universal files when compared to WaveOne single file⁽³²⁾. On the other hand, lower incidence and severity of post-instrumentation pain and postoperative pain were detected in patients treated with ProTaper Universal system in comparison to WaveOne system⁽³³⁻³⁵⁾. Also, One Shape system resulted in a high intensity of postoperative pain after using it, which was not statistically significant when compared to ProTaper Next multi-file system and statistically significant when compared to Revo-S multi-file system⁽³⁶⁾. The results of other studies revealed that there was no difference in postoperative pain between the single-file and multi-file root canal instrumentation techniques evaluated in their researches^(25,26).

In asymptomatic chronic periapical lesion, a state of balance is present between the host defense and the infected canal microbiota. If this balance is disrupted by the extrusion of infected debris, irrigants and/or microorganisms apically during chemomechanical preparation, an acute inflammatory response will occur in order to regain the equilibrium, which in turn could result in postoperative pain and flare-ups⁽²⁹⁾. Forcing these irritants will elicit inflammation whose intensity depends on the quantity and the quality of the extruded debris, the more the amount of extruded debris, the more intense the inflammatory response will be^(37,38). It is strongly declared by many laboratory studies that apical extrusion of debris occurs with all instrumentation techniques even if root canal preparation ends shorter than the apical foramen⁽³⁹⁻⁴¹⁾.

Regarding the use of XP-endo Finisher, it was noted that XP-endo Finisher resulted in more post-instrumentation pain scores in both groups but without significant difference when compared to no XP-endo Finisher subgroups. The *in-vivo* use of XP-endo Finisher after One Shape and ProTaper

Universal instrumentation techniques has not been well documented. However, it can be assumed that XP-endo Finisher kinematics may result in apical extrusion of debris during mechanical preparation. This was in agreement with a previous study that assessed apical debris extrusion during the instrumentation of oval canals with either ProTaper Next files together with XP-endo Finisher or the self-adjusting file system and found that there was more apical extrusion of debris when XP-endo Finisher was used⁽⁴²⁾. Also, it was proved that XP-endo Finisher resulted in apical extrusion of irrigant similar to that standard needle irrigation and significantly more than EndoVac irrigant activation technique⁽⁴³⁾.

CONCLUSION

Within the limits of the current study; pain recorded after using different instrumentation techniques (with XP-endo Finisher or not) occurred only during the first 24 hours and completely disappeared afterwards. The One Shape system produced less postoperative pain when used in conjunction with XP-endo Finisher.

REFERENCES

1. Udoye Ch, Aguwa E. Flare-up incidence and related factors in adults. *J Dent Oral Hyg.* 2010; 2: 19-22.
2. Sathorn C, Parashos P, Messer H. The prevalence of postoperative pain and flare-up in a single- and multiple- visit endodontic treatment: a systematic review. *Int Endod J.* 2008; 41: 91-9.
3. Siqueira JF and Barnett F. Interappointment pain: mechanisms, diagnosis, and treatment. *Endod Topics.* 2004; 7: 93-109.
4. Imura N and Zuolo ML. Factors associated with endodontic flare-ups: a prospective study. *Int Endod J.* 1995; 28: 261-5.
5. Bane K, Faye B, Sarr M, Niang SO, Ndiaye D, Machtoub P. Root canal shaping by single-file systems and rotary instruments: A laboratory study. *Iran Endod J.* 2015; 10: 135-9.
6. Paqué F, Balmer M, Attin T, Peters OA. Preparation of oval-shaped root canals in mandibular molars using

- nickel-titanium rotary instruments: a micro-computed tomography study. *J Endod.* 2010; 36: 703-7.
7. Taha NA, Ozawa T, and Messer HH. Comparison of Three Techniques for Preparing Oval-shaped Root Canals. *J Endod.* 2010; 36: 532-5.
 8. Leoni GB, Versiani MA, Silva-Sousa YT, Bruniera JF, Pécora JD, Sousa-Neto MD. Ex vivo evaluation of four final irrigation protocols on the removal of hard-tissue debris from the mesial root canal system of mandibular first molars. *Int Endod J.* 2017; 50: 398-406.
 9. Alves FR, Marceliano-Alves MF, Sousa JC, Silveira SB, Provenzano JC, Siqueira JF Jr. Removal of root canal fillings in curved canals using either reciprocating single- or rotary multi-instrument systems and a supplementary step with the XP-Endo Finisher. *J Endod.* 2016; 42: 1114-9.
 10. Peters OA, Schönenberger K, Laib A. Effects of four Ni-Ti preparation techniques on root canal geometry assessed by micro computed tomography. *Int Endod J.* 2001; 34: 221-30.
 11. Gregori MK. Improving endodontic success through use of the EndoVac irrigation system. *Endod Pract.* 2009: 17-20.
 12. Nasseh AA, Brave D. Three-Dimensional Instrumentation: The Promise of Minimally Invasive Preparations. *Dent Today.* 2015; 34: 104-8.
 13. Al-Negrish AR, Habahbeh R. Flare up rate related to root canal treatment of asymptomatic pulpally necrotic central incisor teeth in patients attending a military hospital. *J Dent.* 2006; 34: 635-40.
 14. Pak JG, White SN. Pain prevalence and severity before, during, and after root canal treatment: a systematic review. *J Endod.* 2011; 37: 429-38.
 15. Gambarini G, Testarelli L, De Luca M, Milana V, Plotino G, Grande NM, et al. The influence of three different instrumentation techniques on the incidence of postoperative pain after endodontic treatment. *Ann Stomatol.* 2013; 4: 152-5.
 16. Maggiriias J, Locker D. Psychological factors and perceptions of pain associated with dental treatment. *Community Dent Oral Epidemiol.* 2002; 30: 151-9.
 17. Price DD, McGrath PA, Rafii A, Buckingham B. The validation of visual analogue scale as ratio scale measures for chronic and experimental pain. *Pain.* 1983; 17: 45-56.
 18. Holdgate A, Asha S, Craig J, Thompson J. Comparison of a verbal numeric rating scale with the visual analogue scale for the measurement of acute pain. *Emerg Med.* 2003; 15: 441-6.
 19. Banos JE, Bosch F, Canellas M, Bassols A, Ortega F, Bigorra J. Acceptability of visual analogue scales in the clinical setting: a comparison with verbal rating scales in postoperative pain. *Methods Find Exp Clin Pharmacol.* 1989; 11: 123-7.
 20. Paul-Dauphin A, Guillemin F, Virion JM, Briancon S. Bias and precision in visual analogue scales: a randomized controlled trial. *Am J Epidemiol.* 1999; 150: 1117-27.
 21. Goddard G, Karibe H, McNeill C. Reproducibility of visual analog scale (VAS) pain scores to mechanical pressure. *Cranio.* 2004; 22: 250-6.
 22. Patil AA, Joshi SB, Bhagwat SV, Patil SA. Incidence of Postoperative Pain after Single Visit and Two Visit Root Canal Therapy: A Randomized Controlled Trial. *J Clin Diagn Res.* 2016; 10: 9-12.
 23. Shahi S, Asghari V, Rahimi S, Lotfi M, Samiei M, Yavari H, Shakouie S, Nezafati S. Postoperative Pain after Endodontic Treatment of Asymptomatic Teeth Using Rotary Instruments: A Randomized Clinical Trial. *Iran Endod J.* 2016; 11: 38-43.
 24. Ali SG, Mulay S, Palekar A, Sejpal D, Joshi A, Gufran H. Prevalence of and factors affecting post-obturation pain following single visit root canal treatment in Indian population: A prospective, randomized clinical trial. *Contemp Clin Dent.* 2012; 3: 459-63.
 25. Relvas JB, Bastos MM, Marques AA, Garrido AD, Sponchiado EC Jr. Assessment of postoperative pain after reciprocating or rotary NiTi instrumentation of root canals: a randomized, controlled clinical trial. *Clin Oral Investig.* 2016; 20: 1987-93.
 26. Aminsobhani M, Meraji N, Khoshdel A, Ghorbanzadeh A. The Effect of Root Canal Preparation Using Single Versus Multiple Endodontic Rotary Files on Post-operative Pain, a Randomised Clinical Trial. *Eur Endod J.* 2017; 2: 23.
 27. Saha SG, Gupta RK, Bhardwaj A, Misuriya A, Saha MK, Nirwan AS. Comparison of the incidence of postoperative pain after using a continuous rotary system, a reciprocating system, and a Self-Adjusting File system in single-visit endodontics: A prospective randomized clinical trial. *J Conserv Dent.* 2018; 21: 333-8.
 28. Torabinejad M, Cotti E, Jung T. Concentrations of leukotriene B4 in symptomatic and asymptomatic periapical lesions. *J Endod.* 1992; 18: 205-8.
 29. Siqueira JF Jr. Microbial causes of endodontic flare-ups. *Int Endod J.* 2003; 36: 453-63.

30. Caviedes-Bucheli J, Moreno JO, Carreno CP, Delgado R, Garcia DJ, Solano J, et al. The effect of single-file reciprocating systems on Substance P and Calcitonin gene-related peptide expression in human periodontal ligament. *Int Endod J.* 2013; 46: 419-26.
31. Jain N, Gupta A, Meena N. An insight into neurophysiology of pulpal pain: facts and hypotheses. *Korean J Pain.* 2013; 26: 347-55.
32. Shokraneh A, Ajami M, Farhadi N, Hosseini M, Rohani B. Postoperative endodontic pain of three different instrumentation techniques in asymptomatic necrotic mandibular molars with periapical lesion: a prospective, randomized, double-blind clinical trial. *Clin Oral Investig.* 2017; 21: 413-8.
33. Oubaid AH, Mehdi JA. Incidence and severity of pain following the usage of three different root canal instrumentation systems. *JODR* 2015; 1: 51-8.
34. Krithikadatta J, Sekar V, Sudharshan P, Velmurugan N. Influence of three Ni-Ti cleaning and shaping files on postinstrumentation endodontic pain – A triple blinded randomized controlled trial. *J Conserv Dent.* 2016; 19: 311-6.
35. Nekoofar MH, Sheykhrezae MS, Meraji N, Jamee A, Shirvani A, Jamee J, Dummer PM. Comparison of the effect of root canal preparation by using WaveOne and ProTaper on postoperative pain: a randomized clinical trial. *J Endod.* 2015; 41: 575-8.
36. Fatima SA, Moinuddin SM. Pain after single visit endodontic treatment using fifth generation file systems –An in vivo study. *Ind J Conserv Endod.* 2017; 2: 107-14.
37. Seltzer S, Naidorf IJ. Flare-ups in endodontics: Etiological factors. *J Endod.* 2004; 30: 476-81.
38. Sipavičiūtė E, Manelienė R. Pain and flare-up after endodontic treatment procedures. *Stomatologija.* 2014; 16: 25-30.
39. Logani A, Shah N. Apically extruded debris with three contemporary Ni-Ti instrumentation systems: an ex vivo comparative study. *Indian J Dent Res.* 2008; 19: 182-5.
40. Tanalp J, Güngör T. Apical extrusion of debris: a literature review of an inherent occurrence during root canal treatment. *Int Endod J.* 2014; 47: 211-21.
41. Caviedes-Bucheli J, Castellanos F, Vasquez N, Ulate E, Munoz HR. The influence of two reciprocating single-file and two rotary-file systems on the apical extrusion of debris and its biological relationship with symptomatic apical periodontitis. A systematic review and meta-analysis. *Int Endod J.* 2016; 49: 255-70.
42. Kfir A, Moza-Levi R, Herteanu M, Weissman A, Wigler R. Apical extrusion of debris during the preparation of oval root canals: a comparative study between a full-sequence SAF system and a rotary file system supplemented by XP-endo finisher file. *Clin Oral Investig.* 2018; 22: 707-13.
43. Azim AA, Aksel H, Margaret Jefferson M, Huang GT. Comparison of sodium hypochlorite extrusion by five irrigation systems using an artificial root socket model and a quantitative chemical method. *Clin Oral Investig.* 2018; 22: 1055-61.