



Evaluation of the Effect of Bovine Bone Graft on the Preservation of Buccal Plate of Extracted Socket

Radwa Abdel Hamid Helal⁽¹⁾, Shadia Abdel Hameed Elsayed⁽²⁾, Fatma Ibrahim Mohamed⁽²⁾,
Hoda Abdel Kader Saleh⁽³⁾ and Fatma Ahmed Khalifa⁽⁴⁾

Codex : 03/1601

dentaljournal.forgirls@yahoo.com

ABSTRACT

In order to preserve the original ridge dimensions following tooth extraction and promote bone regeneration of the residual alveolar socket, various bone grafts and substitutes were used. Among these grafting materials, bovine bone xenograft was used in order to promote bone regeneration. The aim of this study was to evaluate the effect of bovine bone graft on the preservation of buccal plate of bone of extracted socket. Twelve patients with non-restorable maxillary tooth or remaining root were included in this study. They were divided equally into two groups. Group A: augmentation with bovine xenograft was performed after extraction. Group B: Extraction was performed without grafting. Delayed-immediate implants were placed for all patients at eight weeks after extraction. There was no significant difference in buccal cortical plate thickness between the two groups with. There was a significant increase in bone density of the study group at six months postoperatively. It was concluded that buccal plate augmentation by the “pouch technique” is not enough to compensate the bone loss that occurs in the buccal wall after extraction.

INTRODUCTION

In aesthetic areas, any minimal alteration of soft or hard tissue may compromise the final result¹. Extraction socket healing is characterized by resorption of the alveolar bone at the extraction site, decreasing ridge volume and deforming the ridge contour, which consequently impairs placement of osseointegrated implants in ideal positions². More bone loss, occurs at the buccal than at the lingual aspects of the extraction site³. Thus, preservation of alveolar ridge and soft tissue contours

KEYWORDS

Bovine xenograft,
Buccal bone,
Implants

1. Master student, Faculty of Dental Medicine for Girls, Al-Azhar University.
2. Lecturer of Oral and Maxillofacial Department, Faculty of Dental Medicine for Girls, Al-Azhar University.
3. Professor of Oral Radiology, Faculty of Oral and Dental Medicine, Cairo University.
4. Associate Professor of Oral and Maxillofacial Surgery, Faculty of Dental Medicine for Girls, Al-Azhar University.

by placement of bone grafts was recommended by many studies^{4,5}. Buccal plate preservation, by creating a surgical pouch, is a new technique that aimed to maintain or improve the appearance and contours of the soft and hard tissues after tooth extraction.

Bovine xenograft has the primary inorganic natural component of bone, hydroxyapatite, which is highly biocompatible and bonds readily to adjacent hard and soft tissues⁶. It also provides a natural architectural matrix as well as a natural source of calcium⁵. Additionally it maintains the physical socket dimension^{7,8}. Cone beam computed tomography (CBCT) can be used to quantitatively assess buccal bone thickness with high precision and accuracy⁹. Advantages of CBCT includes shorter examination time, the reduction of image unsharpness caused by the translation of the patient, reduced image distortion due to internal patient movements, and increased x-ray tube efficiency. However, its main disadvantage, especially with larger field of views (FOVs), is a limitation in image quality related to noise and low contrast resolution because of the detection of large amounts of scattered radiation¹⁰.

The aim of this study was to evaluate the effect of bovine bone graft on the preservation of buccal plate of bone of extracted socket by the use of buccal plate preservation technique and CBCT was used to evaluate buccal bone thickness.

PATIENTS AND METHODS

Twelve patients (4 males and 8 females) with non-restorable single anterior maxillary tooth were included in this study, with mean age of 31.6 years. Atraumatic dental extraction was performed for all the patients. Buccal plate augmentation was performed at the time of extraction for the patients of the study group. Bovine xenograft was placed underneath the soft tissue, overlying the buccal plate, in a surgically created pouch, figure (1). Delayed-immediate implants were placed for all patients at eight weeks after extraction, figure (2).

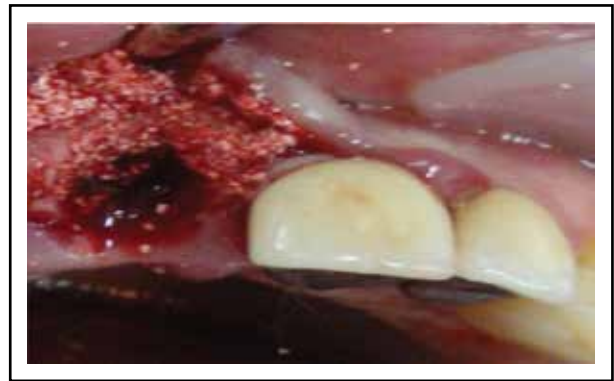

Fig. (1) Intra-operative photograph showing bone graft in a buccally created pouch.

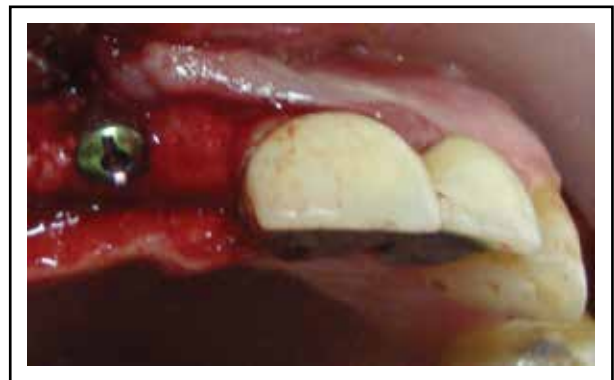

Fig. (2) Intra operative photograph showing Implant in place.

Follow up scan:

Buccal plate thickness and density were recorded preoperatively, 3 and 6 months after implant placement, in a standardized manner using CBCT scans. The scanning conditions were: anode voltage 57 - 85 kV and anode current 10 mA.

Buccal cortical plate thickness measurement:

Buccal cortical plate thickness measurement was performed at three points (implant tip, implant vent and 2mm below the crest of the ridge) with the aid of ruler tool (Figure 3).

The base line reading of buccal cortical plate thickness is measured by selecting virtual implants, which simulate the real inserted implants in length, diameter and shape. After selection of virtual implant, we superimpose it considering that

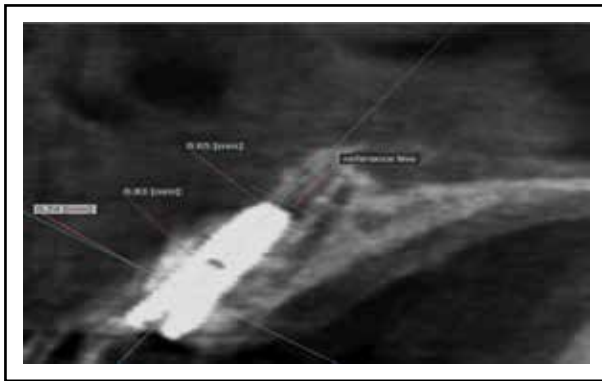


Fig. (3) Showing measurement of buccal cortical plate thickness

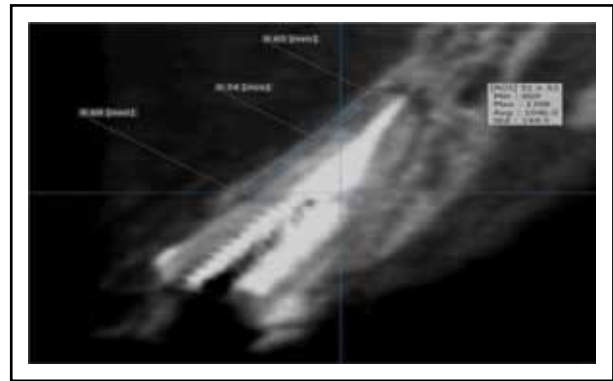


Fig. (5) Showing bone density measurement.

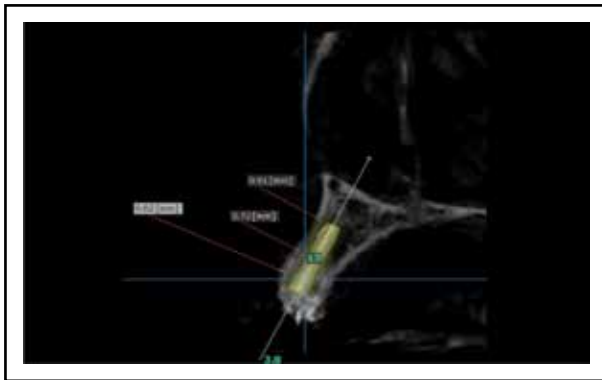


Fig. (4) Showing preoperative virtual implant with the same dimensions and angulations as the actual one.

superimposition should be typical in all directions and the measurements were performed at the same three points (Figure 4).

Bone density measurement

With the aid of region of interest (ROI) tool, selection of the area of buccal cortication was performed representing it as a rectangle with certain dimension to gain the reading of bone density of the first scan (Figure 5).

The same rectangle with the same area and dimension (using the reference points taken for measurement) to obtain the reading of bone density of follow up scans.

Statistical analysis

For statistical analysis, the latest version of IBM® SPSS® 20 was used. Data were presented as Mean \pm standard deviation (SD). All the recorded density readings were in Hounsfield units (HU). Comparisons of the buccal cortical plate thickness and density values between the two groups were made with the independent t-test.

RESULTS

There was no laceration to the soft tissue or fracture of root or buccal plate of bone related to the extracted tooth (in both groups). After buccal plate augmentation, patients showed immediate improvement in the ridge contour, the graft mimic the presence of root eminence as prior to extraction.

In the second stage surgery for implant placement (eight weeks after extraction) some granules of the graft was observed after minimal reflection of the buccal flap in all patients of the study group. Patient number one (in the study group) showed failure in implant placement due to insufficient buccal cortical plate of bone.

Radiographically, there was an increase in buccal cortical plate thickness in the study group throughout the follow up durations with no statistically significant difference. There was no statistically significant difference in the buccal cortical plate thickness in the control group. Additionally no

statistically significant difference in the buccal cortical plate thickness was observed between the study group and the control group throughout the follow up durations, (Table 1, Figure 6).

There was an increase in bone density in the study group with statistically significant difference at six months, (Table 2, Figure 7). There was an increase in bone density in the control group throughout the follow up durations with no statistically significant difference. There was no statistically significant difference in the percentage change between the two groups throughout the follow up durations (Table 3, Figure 8).

Table (1) The percentage of change of buccal cortical plate thickness at the different follow up durations for both groups.

Intervals	Control group		Study group		Mann-Whitney Test	
	Mean	SD	Mean	SD	Z	p-value
3 months	3.23%	3.88	18.55	26.01	-1.601	0.109
6 months	2.60%	7.10	19.37	26.04	-1.441	0.150

Table (2) The percentage of change of bone density at the different follow up durations in the study group.

Percentage change	Density		Paired t-test	
	Mean	SD	t	p-value
3 months	0.34%	0.52%	2.775	0.039*
6 months	0.46%	0.57%		

Table (3) The percentage change of bone density measurements for both groups

Intervals	Study group		Control group		Independent t-test	
	Mean	SD	Mean	SD	t	p-value
3 months	0.345%	0.52	0.23%	0.25	0.467	0.650
6 months	0.46%	0.57	0.35%	0.39	0.390	0.704

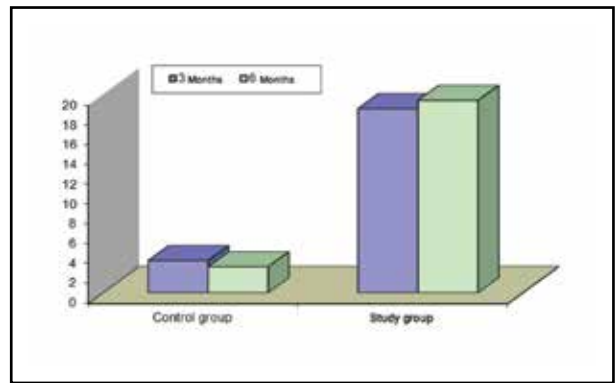


Fig. (6) Bar graph showing percentage of change of buccal cortical plate thickness in both groups.

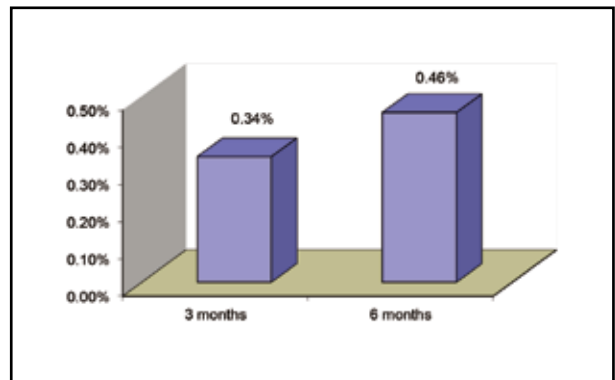


Fig. (7) The percentage of change of bone density at the different follow up durations in the study group.

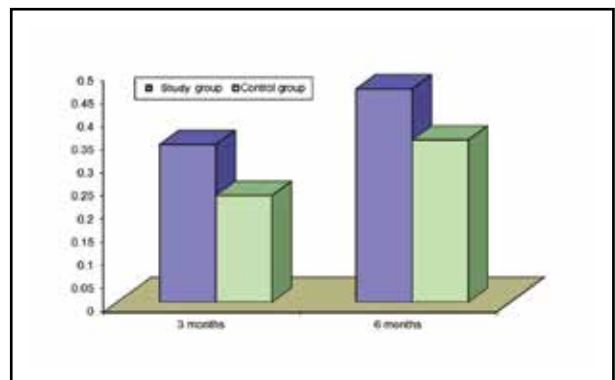


Fig. (8) Bar graph showing percentage change of bone density values for both groups.

DISCUSSION

Preservation of alveolar ridge and soft tissue contours by placement of particulate bone graft material, underneath the soft tissues in a surgically created pouch adjoining the buccal plate has been advocated to prevent recession of the facial wall

of the extraction socket without interfering with its natural self healing process¹.

CBCT can be used to quantitatively assess buccal bone thickness with high precision and accuracy, as reported by Adam, et al. (2011)⁹. CBCT was used in this study to provide quantitative assessment about the changes in buccal bone thickness and density in the anterior maxillary area.

In this study buccal plate augmentation was performed using bovine xenograft, which has the primary inorganic natural component of bone, hydroxyapatite, which is highly biocompatible and bonds readily to adjacent hard and soft tissues⁶.

In the present study 11 implants were clinically stable with no mobility was seen with any of these implants, after span of six months. There were no complications as inflammation, pain or altered sensation observed.

In the study group an implant was failed to be placed in one case as the buccal plate was very thin and there was a defect of 1.15 mm length, 2mm near to the root apex. This is regarding to the initial thickness of maxillary facial bone overlying maxillary anterior teeth which has a significant impact on the responding level of facial bone and soft tissue after extraction¹¹. This technique may only be applied when the natural architecture is intact, and the buccal plate is present as reported by Caiazzo, et al. (2013)⁴. Recent findings suggest that extensive resorption of even intact buccal plates is a common phenomenon following tooth removal^{11,12}. Furthermore, a flap technique for implant insertion causes disruption of the blood supply to the buccal bone wall (made of cortical bone without a medullary component) which will predispose a more evident bone resorption¹³. This remodeling in response to inadequate blood supply becomes more critical at the facial area of the anterior maxillae for characteristics naturally inherent to this region's nature and anatomy¹⁴. Additionally there was a delay of bone formation in the grafted site as reported by Heberer, et al. (2011)¹⁵. Hence eight weeks wasn't enough for bone graft integration.

In the second stage surgery (8-10 weeks after extraction and augmentation) new bone was not expected to be found and the graft particles were partially integrated in the buccal bone in a connective-tissue-like matrix in all the cases of the study group. There is an agreement that a healing period of 8-10 months after tooth extraction and socket augmentation can be used for implantation protocol^{1,16}. Meanwhile Heinemann, et al. (2012)¹⁶ observed that the large benefit of this technique is the availability of a sufficient amount of soft tissue for stress-free socket closure and consequently their preservation.

In spite of the increase of buccal cortical plate thickness in the study group compared to the control group, there was no statistically significant difference between the two groups throughout the follow up durations. This was due to the insufficiency of bone grafting material that used for augmentation.

There was an increase in bone density in the study group throughout the follow up durations with statistically significant difference at six months from implant placement (eight months after extraction and augmentation). This was attributed to the increase of bone tissue area, trabecular thickness and number with a low trabecular separation in the grafted area. This trabecular bone had a compact structure with abundant thick trabeculae¹.

CONCLUSIONS

Buccal plate augmentation by pouch technique isn't sufficient in compensating the bone loss that occurs in the buccal wall. The use of bovine xenograft increases the buccal cortical plate density after eight months. The use of bovine xenograft needs a delayed implantation protocol. CBCT assessment of the quantitative changes of buccal plate is possible and informative, and in most cases is sensitive enough to ascertain the presence or absence of the thin alveolar facial bone in the anterior maxilla. CBCT may be a useful tool for determining the *invivo* bone density.

REFERENCES

1. Villanueva-Alcojol L, Monje F, González-García R, Moreno C, Monje A: Characteristics of newly formed bone in sockets augmented with cancellous porous bovine bone and a resorbable membrane: microcomputed tomography, histologic, and resonance frequency analysis. *Implant Dentistry* 2013; 22: 380-7.
2. Orlamari PVP, Navarro RL, Henriques JFC, Taga R, Cestari TM, Janson G, Granjerio JM: evaluation of bone height and bone density after tooth extraction: an experimental study in minipigs. *Oral Surg Oral Med Oral Pathol Oral Radiol Endod.* 2007;104:e9-16.
3. Röhlig BG, Meriç U, Haluk Keskin H: Clinical and radiographic outcomes of implants immediately placed in fresh extraction sockets. *Oral Surg Oral Med Oral Pathol Oral Radiol Endod* 2010;109:e1-e7.
4. Caiazzo A, Brugnamì F, Mehra P: Buccal plate preservation with immediate postextraction implant placement and provisionalization: Preliminary results of a new technique. *Int J Oral Maxillofac Surg* 2013; 42: 666–70.
5. Allegrini SJr, Koenig BJr, Allegrini MR, Yoshimoto M, Gedrange T, Fanghaenel J, Lipski M: Alveolar ridge sockets preservation with bone grafting – review. *Ann Acad Med Stetin* 2008; 54: 70–81.
6. Misch CE, Dietsch F: Bone grafting materials in implant dentistry. *Implant Dent* 1993; 2: 158-67.
7. Hatano N, Shimizu Y, Ooya K: A clinical long-term radiographic evaluation of graft height changes after maxillary sinus floor augmentation with 2:1 autogenous bone/xenograft mixture and simultaneous placement of dental implants. *Clin Oral Implants Res* 2004; 15:339.
8. Chiapasco M, Zaniboni M, Boisco M: Augmentation procedures for the rehabilitation of deficient edentulous ridges with oral implants. *Clin Oral Implant Res* 2006; 17:136-59.
9. Adam M, Timock, Cook V, McDonalds T, Leo MC, Crowe J, Benninger BL, Covell Jr DA: Accuracy and reliability of buccal bone height and thickness measurements from cone-beam computed tomography imaging. 2011; 140: 734-44.
10. Scarfe WC, Farman AG: What is Cone-Beam CT and How Does it Work? *Dent Clin N Am* 2008; 52: 707-30.
11. Raes F, Cosyn J, Crommelinck E, Coessens P, De Bruyn H: Immediate and conventional single implant treatment in the anterior maxilla: 1-year results of a case series on hard and soft tissue response and aesthetics. *J Clin Periodontol* 2011; 38: 385–94.
12. Cosyn J, Hooghe N, De Bruyn H: A systematic review on the frequency of advanced recession following single immediate implant treatment. *J Clin Periodontol* 2012; 39:582–9.
13. Barone A, Ricci M, Romanos GE, Tonelli P, Alfonsi F, Covani U: Buccal bone deficiency in fresh extraction sockets: a prospective single cohort study. *Clin. Oral Impl Res* 2014; 1–8.
14. Novaes, AB Jr, Macedo GO, Suaid FA, Barros RR, Souza, SL, Silveira E, Souza AM: Histologic evaluation of the buccal and lingual bone plates in anterior dog teeth: possible influence on implant dentistry. *J Periodontol* 2011; 82: 872–7.
15. Heberer S, Al-Chawaf B, Jablonski C, Nelson JJ, Lage H, Nelson K: Healing of ungrafted and grafted extraction sockets after 12 weeks: a prospective clinical study. *Int J Oral Maxillofac Implants* 2011; 26: 385-92.
16. Heinemann F, Hasan I, Schwahn C, Bourauel C, Mundt T: Bone level change of extraction sockets with Bio-Oss collagen and implant placement: a clinical study. *Annals of Anatomy* 2012; 194: 508-12.