



Clinical and Radiographic Assessment of an Innovative Pulpotomy Technique Compared to Conventional in Primary Molars (Randomized Clinical Trial)

Basma M. Kharbotly ^{1*}, Mervat I. Fawzy ², Mohammed H. Mostafa ³, Latifa M. Abdelgawad ⁴

Codex : 79/20.10

azhardentj@azhar.edu.eg

http://adjg.journals.ekb.eg

DOI: 10.21608/adjg.2020.13159.1151

Pediatric Dentistry & Orthodontics
(Pediatric Dentistry, Orthodontics)

ABSTRACT

Purpose: The purpose of this study was to access post-operative clinical as well as radiographic success of Diode Laser / Mineral Trioxide Aggregate (MTA) and Diode Laser /Biodentine (BD) pulpotomy procedures in comparison to conventional technique using Formocresol /Zinc Oxide Eugenol (FC/ZOE) pulpotomy for human primary molars. **Materials and Methods:** A total of 90 lower primary molars that had deep carious lesion and need pulpotomy treatment from 66 healthy and cooperative patients, aged 4-6 years old were chosen for this study. After removal of the coronal tissue and depending on the type of radicular pulp medicament, the teeth were divided randomly and equally into three groups; Group A (FC/ZOE), Group B (Diode Laser/MTA) and Group C (Diode laser/BD). Treatments in all groups were completed with Glass Ionomer restoration then stainless steel crowns. **Results:** The cumulative clinical and radiographic success rates after 12 months follow up were 90.3%, 96.3% and 100% for the FC/ZOE, Diode Laser/MTA and Diode Laser/BD pulpotomy groups respectively. **Conclusion:** Laser assessed pulpotomy in combination with MTA or Biodentine had a more advanced clinical and radiographic success rate correlated to FC/ZOE pulpotomy technique in primary molar. Statistically, no significance difference was found between the three study groups in the overall clinical and radiographic success rate.

KEYWORDS

Pulpotomy,
Diode Laser,
Mineral Trioxide Aggregate (MTA),
Biodentine.

INTRODUCTION

In pediatric dentistry, one of the most important goals is to maintain the primary dentition till eruption of permanent one ⁽¹⁾. Pulpotomy

• Paper extracted from Doctor Thesis titled “Clinical and Radiographic Assessment of an Innovative Pulpotomy Technique Compared to Conventional in Primary Molars (Randomized Clinical Trial)”

1. Assistant lecturer of Pedodontic and Oral Health, Misr University for Science and Technology, Cairo, Egypt
2. Professor of Endodontics, Faculty of Dental Medicine for Girls, Al-Azhar University, Cairo, Egypt
3. Assistant Professor of Pedodontics and Oral Health, Faculty of Dental Medicine for Girls, Al-Azhar University, Cairo, Egypt
4. Professor of Medical Applications of LASER- the National Institute of Laser Enhanced Science. Cairo University, Cairo, Egypt

* Corresponding author email: bassma.kharbotly@gmail.com

technique is performed when accidental or carious exposure of dental pulp happens in painless tooth with a deep carious lesion and without periradicular pathology, this is achieved by cutting of the pulp tissues in the pulp chamber and then covering the radicular pulp stump by a medicated dressing to keep radicular pulp tissue vital⁽²⁾. Classically, formocresol (FC) was expressed as the gold standard pulp dressing material for pulpotomized primary molars⁽³⁾, but concerns against the use of FC in humans as it has a deleterious effects, possible carcinogenic action, mutagenicity and cytotoxicity have been raised⁽⁴⁾.

Moreover, many studies demonstrated that the clinical success of FC pulpotomies decline as time pass⁽⁵⁾. In order to decrease the mischievous effects of the FC, laser irradiation in vital pulp therapy has been offered as a promising substitute. Laser has the ability to control hemorrhage. It has bactericidal effect as well as a stimulation effects on the dental pulp cells. It is faster in action, user-friendly and welcomed by the patient^(6,7).

New innovations and researches in dentistry endorsed new materials that are bioinductive and regenerative like MTA and BD which had biocompatibility, alkalinity and sealing ability for pulp tissue. However BD showed shorter setting time, easily handling properties and higher mechanical properties with no discoloration potential^(8,9). Profit of combing Diode Laser and regenerative materials as a pulpotomy technique in primary teeth are promising and open an era for further researches⁽¹⁰⁻¹²⁾.

MATERIALS AND METHODS

This research was authored as stated in the Consolidated Standards of Reporting Trials (CONSORT) statement⁽¹³⁾. It is a double-blinded randomized clinical trial.

Patient selection:

Total of 90 lower right and left primary molars with deep carious lesions from 66 healthy and cooperative patients, aged 4-6 years old and need

pulpotomy treatment were selected for this study. The children were diagnosed, selected, treated and followed up in the clinics of Pedodontic department, Faculty of Dental Medicine for Girls, Al-Azhar University and the National Institute of Laser Enhanced Science (NILES) –Cairo University. The children were 31 male and 35 female.

Ethical consideration:

Written informed consent was gained. Research Ethics Committee approval was taken from Faculty of Dental Medicine for Girls, Al-Azhar University.

Randomization:

- Regulated by the type of radicular pulp medication, the lower molars were branched randomly and equally into three groups using envelopes simple randomization as following: **Group A** (FC/ZOE pulpotomy group), **Group B** (Diode Laser/MTA pulpotomy group) and **Group C** (Diode Laser/BD pulpotomy group).

Inclusion Criteria⁽¹²⁾:

Clinically the primary molar must be symptomless with a deep carious lesion. There must be no swelling, tenderness on percussion, sinus trace opening, pathological mobility or spontaneous pain. Molars must be restorable after finishing of the procedure.

Radiograph criteria constituted no internal resorption, no interradicular bone destruction, no periapical bone destruction and no loss of the lamina dura /widening of periodontal ligament space. Presence of permanent successor must be evident.

Exclusion Criteria⁽¹²⁾:

Including excessive bleeding during pulp amputation, non vital/necrotic teeth, any sort of medical history contraindicating the pulp treatment, teeth approximate exfoliation, patient gradient not intending to be part of the study and retreatment of previously pulpotomy treated molar.

Diagnosis of cases:

Before treatment, a thorough medical and dental history was earned then a clinical checking and radiographic examination with a standardized paralleling technique employing size 2 films D speed (Kodak Insight, Eastman Kodak, Rochester, NY, USA), an XCP posterior film holder and an X-ray machine (70KVP, 8mA).

Treatment protocol:

Molars were anesthetized by local anesthesia (Septocaine® and epinephrine 1:100,000, Septodont, USA). The rubber dam was used for isolation. Caries removal and deroofting of the pulp chamber was achieved then pulpal tissue amputation with sharp excavator and irrigation was done from the pulp chamber. Subsequent irrigation, initial hemorrhage control was carried out in 3-5 minutes by wet cotton pellets under slight pressure. According to radicular pulp medicament type, the treatment was preceded as following:

- **In Group (A):** Complete hemostasis was obtained by applying small cotton pellet soaked in Formocresol; dried by squeezing over the orifices of the canals for 5 minutes. The FC pellet was then eliminated and pulp stump was dressed with a layer of ZOE paste (Prevest Dent Pro, India) then restored with Glass-Ionomer restoration (EQUIA fort® system (Fil & coat) GC corporation, Tokyo, Japan. ALSIP, IL 60803).
- **In Group B:** After initial hemostasis was gained, the 30 molars were managed by exhibiting root canal orifices to 810nm Diode Laser applied in continuous mode for 1-2 seconds using 400 microns optical fiber tip in contact mode with 1.5 watt power^(14,15). Pulp stumps were topped with MTA paste. Wet cotton pellet was located in pulp chamber, and cavity was topped with intermediate restorative material (IRM). In the second session 1 day after, patients were recalled and cotton pellet was eliminated. Cavity was repaired with Glass-Ionomer restoration.

- **In Group C:** The 30 molars were handled after initial hemostasis by displaying root canal orifices to diode laser exactly as in group B then Biodentine mixture allocated in the pulp chamber and allowed to finish setting completely then restored with Glass-Ionomer restoration. Treatment in the three groups was completed with stainless steel crown and immediate post operative radiograph was done.

Follow up and outcome evaluation:

Clinical and radiographic monitoring of the treated molars at 1, 3, 6, 9, and 12 months was done. The clinical evaluation and periapical radiographs were done in every follow up visit using same parameters as preoperative radiograph; data were documented in the patient evaluation and follow up form.

Outcome assessment criteria**a- Clinical evaluation criteria:**

Teeth showing the following characters were considered as success: free of pain symptoms on percussion as well as during mastication, pathological mobility absence, no swelling of pulpal origin and no sinus tract⁽¹²⁾.

b- Radiographic evaluation criteria:

Teeth demarcating the following criteria were accepted as success: no internal root resorption, no external root resorption, no periapical or furcation radiolucency and no widening of periodontal ligament space⁽¹²⁾.

RESULTS

Chi-squared test declare that no statistical difference between the three groups in the cumulative clinical and radiographic success rate as well as at each follow up period was found. The clinical and radiographic success after 12 months follow up for FC/ZOE, Diode Laser/MTA and Diode Laser/BD pulpotomy groups were 90.3%, 96.3% and 100% respectively.

Clinically, the three study groups showed 100% success rate at 1,3, 6 and 9months check up period. At the last follow up period, the clinical success rate decreased in FC/ZOE group to 90.3% with three cases showed swelling, two of them had pain, abscess and pathological mobility. Diode Laser/MTA group showed 96.3% clinical success as one case showed pathological mobility and swelling with pain. Diode Laser/BD group showed 100% clinical success rate(Fig.1).

Radiographically, the present study showed 100% success in the three study groups till 6 months follow up. At 9 months follow up, the radio-

graphic success rate in FC/ZOE group was 93.3% as two cases showed internal/external root resorption while the success rate was 100% for Diode Laser / MTA and Diode Laser /BD groups. At 12 months follow up period, the FC/ZOE group had 90.3%, success rate. There were three cases showed failure in form of periodontal ligament space widening and internal/external root resorption. Additionally, one case of them showed periapical radiolucency. In Diode Laser /MTA group, the success rate was 96.3%.One case showed periodontal ligament space widening and bone radiolucency. In Diode Laser / BD group, the success rate was 100% (Fig.2).

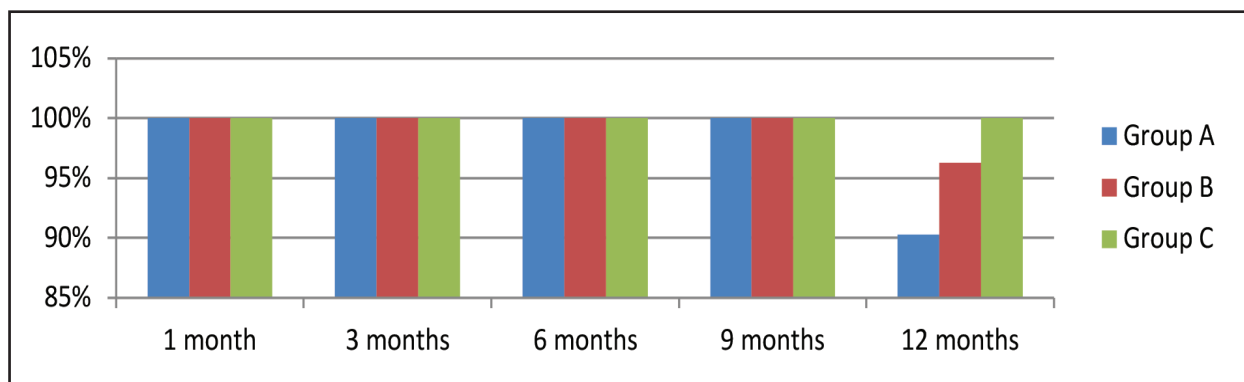


Figure (1) Bar chart showing percentage of clinical success at 1,3,6,9 and 12 months follow up in FC/ZOE group (Group A), Diode Laser/MTA group (Group B) and Diode Laser/BD group (Group C).

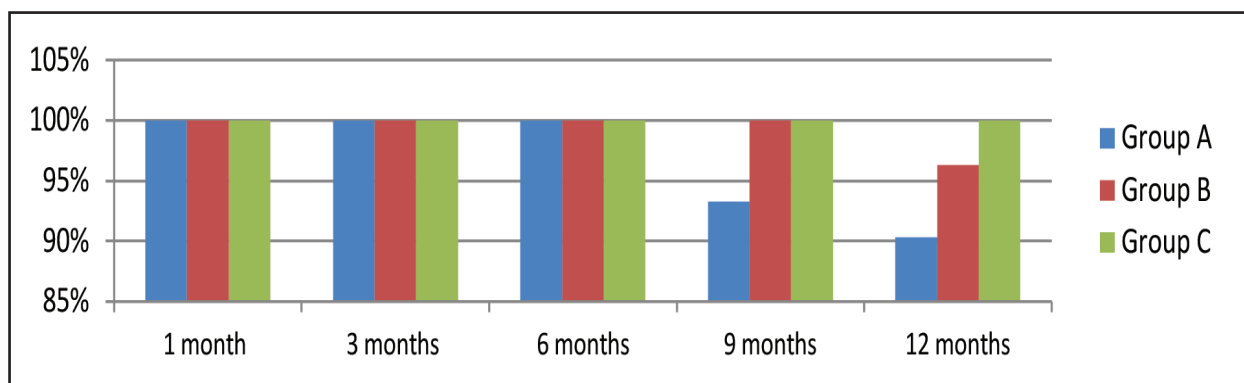


Figure (1) Bar chart showing percentage of radiographic success at 1,3,6,9 and 12 months follow up in FC/ZOE group (Group A), Diode Laser/MTA group (Group B) and Diode Laser/BD group (Group C).

DISCUSSION

This research was implemented to determine the effectiveness of primary molars pulpotomy using Diode Laser combined with MTA or Biodentine in an attempt to reach for the best successful pulpotomy technique to replace FC pulpotomy. It was a double blinded study, as both participants and statistician were blinded. RCT is the gold standard for a clinical trial and the highest level of evidence⁽¹⁶⁾.

The success rate of this research after 12 months follow up was 90.3%, 96.3% and 100% for FC/ZOE group, Diode Laser/MTA group and Diode laser/BD group respectively. According to Chi-squared test, differences between the three groups in this study were not statistically significant. This goes in agreement with the findings of another study in which it used laser /MTA pulpotomy, no significant difference was seen between the tested materials⁽¹⁷⁾. Systematic reviews as well as meta analysis found no significant difference as well between the different pulpotomy techniques including FC, MTA, BD, Diode laser, Diode laser /MTA^(2,18,19). On the contrary, another systematic review exhibited that MTA and FC had a significant higher results than Laser therapies in pulpotomy of the primary molar⁽²⁰⁾.

Outcomes of the contemporary research agreed with the high clinical and radiographic success rates which were reported for FC/ZOE^(17, 21). However, the present study disagrees with another study that reported a 78.9% success rate for the FC group⁽²²⁾. The clinically failed cases in FC/ZOE pulpotomy group may be clarified as FC fix upper parts of the radicular pulp tissue than to promote healing^(23,24). The pulp tissues at the apical region displayed signs of inflammation, which sequentially increase the probability of pain and periapical changes⁽²²⁾. Formocresol has smaller molecular size that can reach into the apical region through the pulp canals⁽²⁵⁾. Radiographically, the present study results demonstrated internal root resorption in 9.3% (3/30) of the treated molars after 12 months follow up. It

was speculating that the risk of internal root resorption increased in the primary teeth that have been managed with FC as it does not have the capability to induce new dentin deposition⁽²³⁾. A study showed that internal resorption is correlated with Eugenol (from the ZOE past) that cause moderate to severe inflammatory response⁽²⁶⁾. Widening of the periodontal membrane and periapical radiolucency was found to be typical with FC treated teeth due to the FC filtrates into the circumferential tissues leading to inflammatory reaction radiolucency⁽¹⁸⁾.

Regarding Diode Laser /MTA pulpotomy group, the outcomes of this study concurred with preceding studies that emphasized the high success rate of Diode Laser /MTA pulpotomy techniques in primary teeth⁽¹³⁾. High success rate after using Diode Laser in primary teeth pulpotomy could be credited to its non-invasive and non-pharmaceutical nature, powerful ability to control hemorrhage, decontamination and sterilization effect together with its ability to preserve the radicular pulp and to boost pulpal wound healing^(3,6,12). Mineral Trioxide Aggregate high success rate might be due to its superlative sealing ability, biocompatibility, antimicrobial effect and its regenerative ability^(12,25,27-30).

The high success rates in Diode Laser/BD group mirrors the beneficial effect of combining Diode laser with its unique actions as it mentioned before and BD which approve its importance as a highly successful pulpotomy material in primary teeth owing to its ability to stimulate cell differentiation and boost mineralization in the dental pulp cells of the humans as well as its high physico-mechanical properties. It also possess easier handling and less setting time than MTA that allow finishing vital pulpotomy treatment in one visit⁽⁷⁻⁹⁾.

The current study showed high success rate clinically and radiographically as it gathered between Diode Laser advantages and two regenerative materials which were MTA and Biodentine respectively as new pulpotomy techniques in primary teeth. These results agreed with previous studies that

avored as well laser effect before regenerative materials as calcium-enriched mixture cement, MTA and Calcium Hydroxide⁽¹⁰⁻¹²⁾. On the other hand, a previous study used 980-nm diode laser with 3W until hemostasis was carried out before applying MTA and expressed less radiographic success in correlation to FC pulpotomy which suggest thermal damage to pulp cells⁽¹⁷⁾. The parameters used in this study regarding Diode laser output power and time of application in addition to remove the coronal pulpal tissue applying a hand instrument rather than laser and using proper water irrigation as well reflected the improvement in understanding laser method of application and prevented excessive heat generation which corporate previous studies^(14,15).

CONCLUSION

The following could be concluded:

Combination of Diode laser and MTA or BD is uprising pulpotomy technique in primary molars.

ACKNOWLEDGMENT

Special appreciation and deepest gratitude to all members of Pediatric Dentistry department, Al-Azher University-Girls branch for their considerable cooperation and support.

REFERENCES

1. Pinkham JR. Pediatric Dentistry Infancy through Adolescence. 4th ed. W.B. Saunders, 2005.
2. Coll JA, Seale NS, Vargas K, Marghalani AA, Al Shamali S, Graham L. Primary Tooth Vital Pulp Therapy: A Systematic Review and Meta-analysis. *Pediatr Dent*. 2017;39: 116-23.
3. Durmus B, Tanboga I. In vivo evaluation of the treatment outcome of pulpotomy in primary molars using diode laser, formocresol, and ferric sulphate. *Photomed Laser Surg*. 2014;32: 289-95.
4. Shashidhar C, Jyothi S. Formocresol, still a controversial material for pulpotomy: A critical literature review. *J Rest Dent*. 2014;2;3-7.
5. Ranly DM. Pulpotomy therapy in primary teeth: New modalities for old rationales. *Pediatr Dent* 1994;16:4039.
6. Olivi G, Genovese MD, Caprioglio C. Evidence-based dentistry on laser paediatric dentistry: review and outlook. *Eur J Paediatr Dent*. 2009;10:29-40.
7. Niranjani K, Prasad MG, Vasa AA, Divya G, Thakur MS. Clinical Evaluation of Success of Primary Teeth Pulpotomy Using Mineral Trioxide Aggregate ®, Laser and Biodentine (TM)- an In Vivo Study. *J Clin Diagn Res* 2015; 9:35-7.
8. Carti O, Oznurhan F. Evaluation and Comparison of Mineral Trioxide Aggregate and Biodentine in Primary Tooth Pulpotomy: Clinical and Radiographic Study. *Niger J ClinPract*. 2017;20:1604-9.
9. El Meligy OA, Alamoudi NM, Allazzam SM, El-Housseiny AA. Biodentine™ versus formocresol pulpotomy technique in primary molars: a 12-month randomized controlled clinical trial. *BMC Oral Health*. 2019; 19: 3-8.
10. Fernandes AP, Lourenço Neto N, Teixeira Marques NC, Silveira Moretti AB, Sakai VT, Cruvinel Silva T, Andrade Moreira Machado MA, Marchini Oliveira T. Clinical and radiographic outcomes of the use of Low-Level Laser Therapy in vital pulp of primary teeth. *Int J Paediatr Dent*. 2015;25:144-50.
11. Ansari G, Morovati SP, Asgary S. Evaluation of Four Pulpotomy Techniques in Primary Molars: A Randomized Controlled Trial. *Iran Endod J*. 2018 ;13:7-12.
12. Pratima B, Chandan GD, Nidhi T, Nitish I, Sankriti M, Nagaveni S et al.: Postoperative assessment of diode laser zinc oxide eugenol and mineral trioxide aggregate pulpotomy procedures in children: A comparative clinical study. *J Indian Soc Pedod Prev Dent*. 2018;36:308-14.
13. Schulz KF, Altman DG, Moher D, CONSORT Group. CONSORT 2010 statement: updated guidelines for reporting parallel group randomized trials. *Int J Surg*. 2011;9: 672-7.
14. Yilmaz Y, Keles S, Mete A. Temperature changes in the pulpal chamber and the sealing performance of various methods of direct pulp capping of primary teeth. *Eur J Paediatr Dent* 2013;14, 95-100.
15. Yazdanfar I, Gutknecht N, Franzen R. Effects of diode laser on direct pulp capping treatment: a pilot study. *Lasers Med Sci* 2015; 30:1237-43.
16. Patricia B. Burns, Rod J. Rohrich, Kevin C. Chung. The Levels of Evidence and their role in Evidence-Based Medicine. *Plast Reconstr Surg*. 2011; 128: 305-10.

17. Saltzman B, Sigal M, Clokie C, Rukavina J, Titley K, Kulkarni GV.: Assessment of a novel alternative to conventional formocresol-zinc oxide Eugenolpulpotomy for the treatment of pulpally involved human primary teeth: Diode laser-mineral trioxide aggregate pulpotomy. *Int J Paediatr Dent* 2005; 15:437-47.
18. Smaïl-Faugeron V, Glenny AM, Courson F, Durieux P, Muller-Bolla M, FronChabouis H. Pulp treatment for extensive decay in primary teeth. *Cochrane Database Syst Rev*. 2018 ;31:5-10.
19. Ansari G, Safi Aghdam H, Taheri P, GhazizadehAhsaieM. Laser pulpotomy-an effective alternative to conventional techniques-a systematic review of literature and meta-analysis. *Lasers Med Sci*. 2018; 33:1621-9.
20. Lin PY, Chen HS, Wang YH, Tu YK. Primary molar pulpotomy: a systematic review and network meta-analysis. *J Dent*. 2014 ; 42:1060-77.
21. Peng L. Evaluation of formocresol versus ferric sulphate primary molar pulpotomy: A systematic review and meta-analysis. *Int Endod J*.2007; 40: 751–7.
22. Jamali Z, Alavi V, Najafpour E, Aminabadi NA, Shirazi S. Randomized Controlled Trial of Pulpotomy in Primary Molars using MTA and Formocresol Compared to 3Mixtatin: A Novel Biomaterial. *J Clin Pediatr Dent*. 2018;4:361-6.
23. Jabbarifar SE, Khademi AA, Ghasemi D. Success rate of formocresol pulpotomy versus mineral trioxide aggregate in human primary molar tooth. *J Res Med Sci* 2004;9:304-7.
24. Holan G, Eidelman E, Fuks AB. Long-term evaluation of pulpotomy in primary molars using mineral trioxide aggregate or formocresol. *Pediatr Dent* 2005;27:129- 36.
25. Eidelman E, Odont D, Holan G, Fuks AB. Mineral trioxide aggregate vs. formocresol in pulpotomized primary molars: a preliminary report. *JPD*, 2001;23: 15–18.
26. Gonzalez-Lara A, Ruiz-Rodriguez MS, Pierdant-Perez M, Garrocho-Rangel JA, Pozos-Guillen AJ. Zinc Oxide-Eugenol Pulpotomy in Primary Teeth: A 24-Month Follow-up. *J Clin Pediatr Dent*. 2016; 40:107-12.
27. Agamy HA, Bakry NS, Mounir MM, Avery DR. Comparison of mineral trioxide aggregate and formocresol as pulp-capping agents in pulpotomized primary teeth. *Pediatr Dent*. 2004;26:302-9.
28. Yildiz E and Tosun G. Evaluation of formocresol, calcium hydroxide, ferric sulfate, and MTA primary molar pulpoto-mies. *Eur J Dent*. 2014 ; 8: 234–40.
29. Hugar SM, Reddy R, Deshpande SD, Shigli A, Gokhale NS, Hugar SS: *In vivo* Comparative Evaluation of Mineral Trioxide Aggregate and Formocresol Pulpotomy in Primary Molars: A 60-month Follow-up Study. *Con temp Clin Dent*.2017; 8: 122–7.
30. Jamali Z, Alavi V, Najafpour E, Aminabadi NA, Shirazi S: Randomized Controlled Trial of Pulpotomy in Primary Molars using MTA and Formocresol Compared to 3Mixtatin: A Novel Biomaterial. *J Clin Pediatr Dent*. 2018;4:361-6.